


# Breast Density Bill State of Colorado

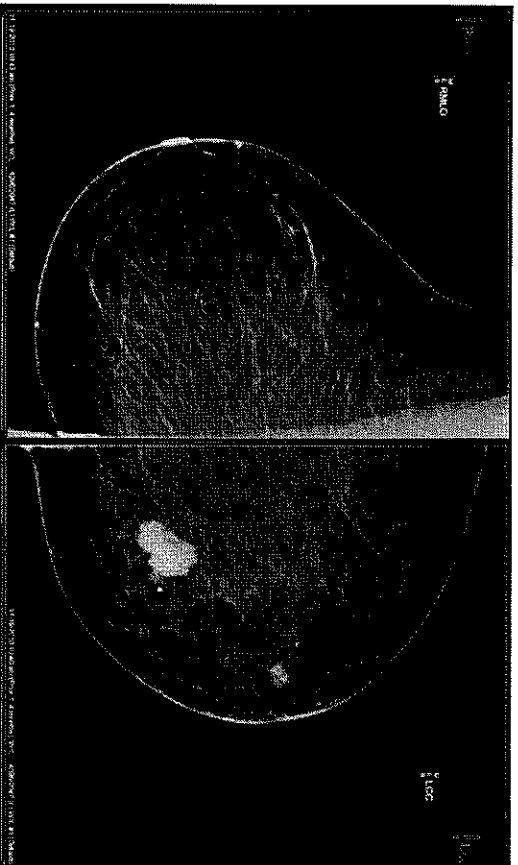
## Our Focus

### EARLY DETECTION OF BREAST CANCER

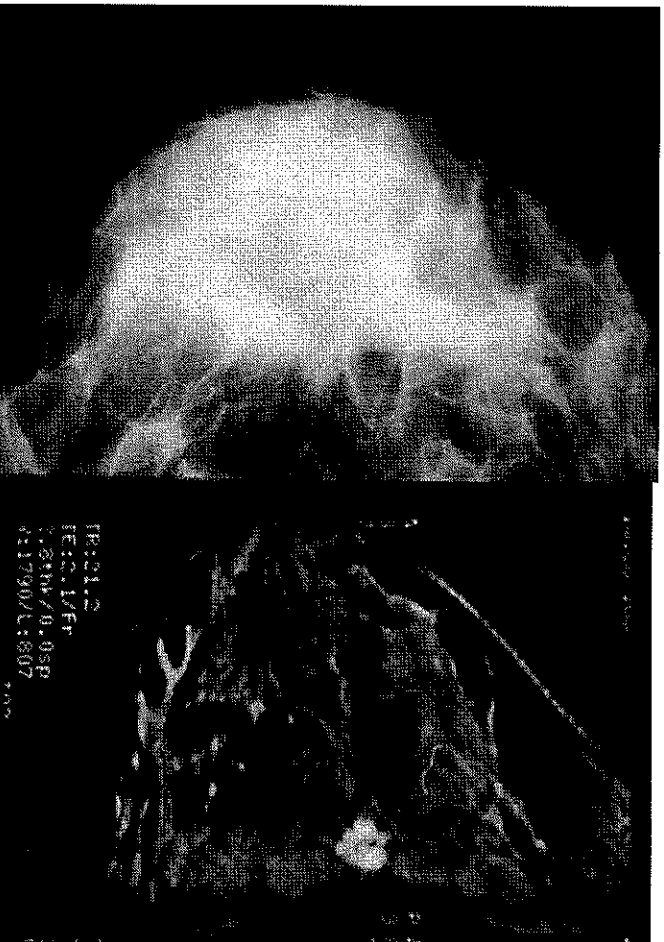


The figures above are illustrations of the four BI-RADS grades of breast tissue density (from left to right) least dense through extremely dense.

## Examples of Differing Types of Breast Tissue



These mammographic images are of primarily fatty (low density) breast tissue. The film on the left shows healthy breast tissue. The film on the right shows several tumors, which are clearly visible within fatty breast tissue. Notice how the tumor shows white on the film:



These images are of dense breast tissue. The mammogram on the left shows extremely dense breast tissue. Imagine how the tumor at the above right would show on this film. The MRI of the same breast on the right clearly shows a breast cancer tumor: These images are of dense breast tissue. The mammogram on the left shows extremely dense breast tissue. Imagine how the tumor at the above right would show on this film. The MRI of the same breast on the right clearly shows a breast cancer tumor: